

Multispectral Optical Examination of Oral Lesions in High-Risk Populations

By Mark Nichols, DDS, Vice President of Clinical Affairs, Bering Omega Dental Clinic

Since 1987, the Bering Omega Dental Clinic in Houston, Texas, has been providing compassionate health care and social services to people living with HIV/AIDS. The dental clinic is the only free and full service HIV/ AIDS dedicated dental clinic in Texas, serving more than 2,000 individuals and accommodating over 15,000 patient visits annually. Our clinic serves approximately one in three HIV-positive people in the Houston/Harris county area.

Caring for a high volume of patients whose immune systems have been compromised places extraordinary demands on my clinical staff, and as Vice President of Clinical Affairs, on me as well. We need clinical tools that are effective and efficient in identifying and diagnosing abnormalities in the oral cavity, especially those that could be precursors to oral cancer. Since mid-June of this year, I have been using the Trimira Identafi™ 3000 handheld multispectral device for examination of patients in my regular practice. As many as 5% of our patient population presents with HPV lesions, and a significant number of them are FEH (focal epithelial hyperplasia, HPV types 13 and 32), also known as Heck's disease. Since I have used the unit in my practice, I have found it to be especially useful for examination of patients with disseminated disease, such as HPV. The convenient device helps me identify suspicious oral lesions and, if necessary, select a site for biopsy.

In preparation for an indentafi™ 3000 exam, a protective disposable cover is placed over the distal half of the device. This is meant to prevent cross-contamination between

patients and ... shorten the down time between examinations that would be needed to sterilize an unprotected device completely. Identafi 3000 disposable covers in the form of dental #4 mirrors are commercially available at this time. We are also evaluating protective covers without mirrors at the Bering Omega Dental Clinic. Trimira expects to add these to its product line. After snapping the disposable cover in place, the provider puts on special filtering goggles. These allow unobstructed white and green-amber light examination with the identafi 3000, while blocking the violet light that is used to excite autofluorescence. The final preparatory step is to dim the room lights to minimize their impact on the visualization of autofluorescence.

The identafi 3000 exam consists of visual evaluation of the oral cavity under the three different lighting conditions provided by the instrument. The first is a white-light evaluation. This view of the oral cavity provides information similar to that gained with a regular dental chair lamp. Often, the ability to place the light source inside the oral cavity will provide better illumination of areas that may be obscured by shadows, such as the areas of the tonsils and [the] base of the tongue.

The second view is with a violet-spectrum light, around 405 nm, which causes autofluorescence in certain tissue types, and is easily visible under the dimmed room light conditions in which the exam is performed. The size and shape of the device make it convenient for examination of the entire oral cavity, including the tongue,

buccal mucosa, gingival, hard and soft palate, and the floor of the mouth. Having identified a region of interest or an abnormality, I use the degree of loss of fluorescence to pick out biopsy sites that may be required. That is, I have biopsied the area that looks darkest in the region of interest (largest loss of fluorescence). The third view of the oral cavity, using green-amber illumination, allows fine visualization of vasculature at and near the tissue surface. To date, I have found the violet autofluorescence view to provide the most additional information to my regular examination.

A Hispanic adult male in his forties presented recently at the Bering Omega clinic with generalized HPV lesions on the labial and buccal mucosa. The lesions were sessile, slightly elevated, and stippled with normal color. Lesions were asymptomatic, but were beginning to increase in size and become of cosmetic and functional concern due to biting. In addition to a conventional oral exam, the patient was evaluated with a Trimira identafi 3000.

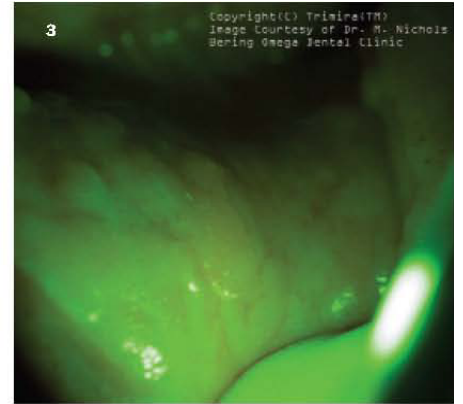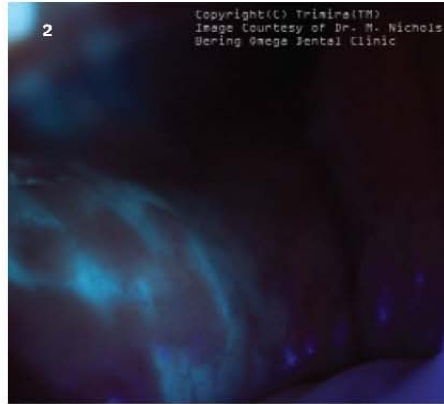
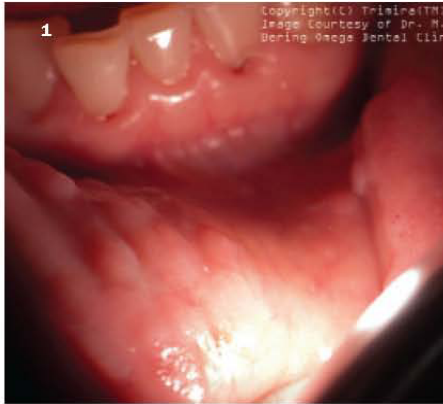White light showed papules characteristic of FEH (Figure 1 - page 42). Illuminating the affected area with the identafi 3000 violet light caused the labial epithelium to appear bright blue, showing darker, red-tinted areas corresponding to the location of HPV lesions (Figure 2 - page 42). The green-amber image showing the vasculature present in the field of interest was also acquired (Figure 3 - page 42). For patients who show suspicious lesions under white-light examination but no loss of fluorescence, I have chosen a

Technology

course of follow-up examination. In this case, however, a biopsy site was selected that showed the most pronounced loss of fluorescence. The biopsy at the selected site showed FEH with moderate dysplasia. The patient is expected back for follow-up treatment with alpha-interferon subcutaneously and cimetadine (Tagamet) at 400 mg TID.

This is just one case of many instances where the Trimira identafi

3000 helped me visualize an oral abnormality, select a specific biopsy site, and treat a dangerous and contagious hyperplastic lesion. Because the clinical exam with the Trimira device took just 2 minutes (5 minutes with photographs taken), I was able to maintain my busy schedule and give the same attention to our high volume of patients. ■



ORAL CANCER STOPS HERE

Identafi® 3000 ultra: Shining an even brighter light on oral cancer detection

-  The ONLY multi-spectral device on the market
-  The ONLY oral cancer screening device utilizing 405nm
-  2x Double the autofluorescence power to ensure enhanced and thorough detection
-  Compact, lightweight, cordless, and handheld device
-  Eliminates the need for messy, bad tasting dyes or solutions

